

Successful treatment of chemotherapy-induced alopecia with LaserCap™: a case report

Tseng-Kuo Shiao, MD, Ting-Kuo Shiao, Jessica C. Shiao *Overland Park, Kansas*; I-Sen Shiao, MD *Taipei, Taiwan* uhr@att.net

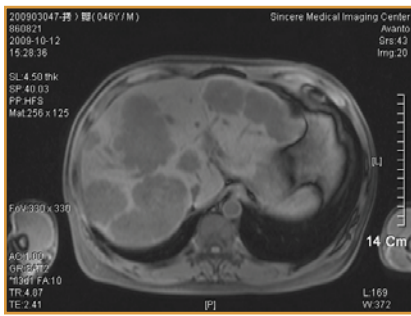


Figure 1. MRI of the liver at the time of diagnosis.

Case report: The patient is a 46-year-old male of Chinese decent diagnosed with stage IV colon cancer with 10+ metastases to the liver on October 12, 2009 (Figure 1). His CEA at the time of discovery was 4,030ng/ml.

FOLFOX (5-FU, folinic acid, oxaloplatin) chemotherapy every two weeks was started on October 28, 2009. Alternative therapy included fermented wheat germ extract (Avenar) and high-dose IV Vitamin C (3,000mg IV, 3 times per week) beginning in the same month and 8g/day of fucoidan from *Fucus vesiculosus* beginning in early December 2009. The patient had minimal side effects from the FOLFOX chemotherapy regimen, reported no GI discomforts, and had no noticeable hair loss during his 12 weeks of FOLFOX.

Unfortunately, the patient's tumors did not respond to the chemo regimen, and his CEA reached 7,900ng/ml by January 2010. His oncologist switched his chemo regimen to cetuximab + FOLFIRI (5-FU, folinic acid, irinotecan) while his alternative therapies remained the same. Under this new regimen, he experienced significant side effects including diarrhea, nausea, skin eruptions, and, within several weeks, significant hair loss.

His colon Ca responded to the new chemo regimen, and his CEA dropped to 396ng/ml in 4 weeks (February 2010) and 359ng/ml in 2 months (March 2010). The patient's CT after 3 months of chemo (April 2010) showed significant reduction of tumor size (< 1/10 of the volume at the time of discovery) and widespread calcification. His fucoidan regimen was changed to a 50/50 mix of *Fucus vesiculosus* and *Undaria pinnatifida* at the end of March 2010. The same chemo protocol continued and his CEA dropped to 12.40 by July 2010 and his CT at the end of July also showed reductions in tumor size and count. As of July 31, 2010, the patient is still on the same protocol.

LaserCap Treatment

Hoping to stop the patient's hair loss, in April 2010 Drs. Tseng-Kuo and I-Sen Shiao had started the patient on LaserCap treatment. LaserCap is a portable low level laser therapy device containing 224-650nm 5mw laser diodes. The patient received 30-minute LaserCap treatments 2-3 times a week. By June 2010, after 23 sessions (about 9 weeks of LaserCap therapy), the patient's hair loss had completely stopped. He had also regained his lost hair and may have had a higher hair density than he did prior to chemotherapy (Figure 2). The patient did not use minoxidil, because it irritated his already compromised skin (from cetuximab).

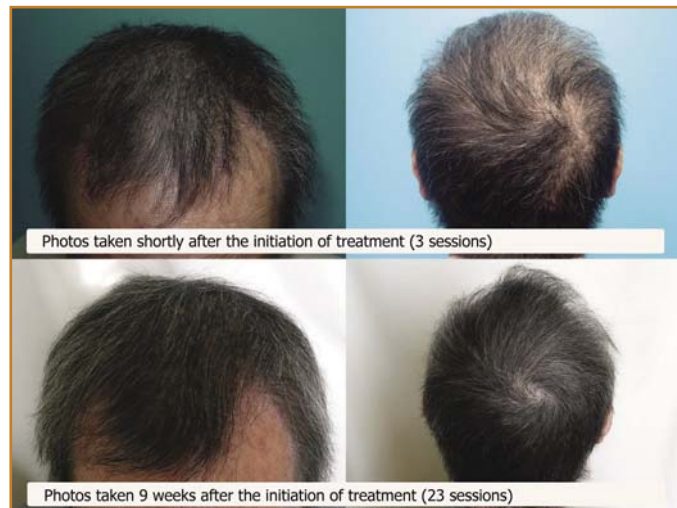

Figure 2. Pictures in the top row were taken 10 days (3 treatment sessions) after initiation of LaserCap therapy. Note the significant hair loss in these pictures. Pictures in the bottom row were taken about 9 weeks (23 treatment sessions) after initiation of LaserCap therapy. Not only did the patient's hair loss stop, his hair also grew back while he was under active chemotherapy (note the skin eruption on left forehead due to cetuximab).

Discussion

Few dermatologic conditions carry as much emotional distress as chemotherapy-induced alopecia. It is psychologically daunting as it constantly reminds the patient of the disease, and patients have even refused possibly palliative or lifesaving drugs because they could not accept the temporary or prolonged baldness. In this patient's case, once his hair loss ceased, his family members noticed a change in his mood from being depressed to being much more relaxed. In his words, "It was very depressing to see hair all over my pillow when I got up every morning and to watch gobs of hair falling off each time I combed my hair. Now I feel bad for other chemo recipients who do not have access to the LaserCap."

As far as we know, this is the first reported case of successful treatment of hair loss induced by chemotherapy while the patient is undergoing active chemotherapy under the same regimen. However, this is an anecdotal case and controlled studies must be done to determine if low level laser therapy is really useful in chemotherapy-induced alopecia, or if such success is only possible against certain chemotherapeutic agents or influenced by the patient's age, gender, and degree of hair loss. We must also determine if low level laser therapy was solely responsible for the success or if any alternative therapies this patient received, such as fucoidan, fermented wheat germ extract, and IV Vitamin C, also played a role. Nevertheless, we hope this case report will lead to a new direction in finding treatment for chemotherapy-induced alopecia and bring hope to the millions suffering from this heart-wrenching condition. ✧